

## Doctor It Hurts Down There

Ann S. Botash, MD  
April 2014

---

---

---

---

---

---

---

- New York State Department of Health funding supports the presentation of this CHAMP Program educational webcast.
- The purpose of the webcast is to improve the quality of the medical response to suspected child abuse.

---

---

---

---

---

---

---

## Disclosures

- I have no relevant financial interests.
- SUNY Upstate Medical University designates this educational activity for a maximum of (1) AMA PRA Category 1 Credit(s) TM.
- Physicians should only claim credit commensurate with the extent of their participation in the activity.

---

---

---

---

---

---

---

## Learning Objectives

1. Review cases of child abuse and analyze steps for diagnosis and treatment
2. Recognize mimics of child sexual abuse

---

---

---

---

---

---

---

## “Doctor it hurts down there”

- The differential diagnosis of genital pain
  - Genital lesions (trauma, skin conditions)
  - Testicular torsion
  - Tourniquets
  - Dysuria (genital pain but only when the patient urinates—think UTI!)
  - Genital bleeding (pain with bleeding)

---

---

---

---

---

---

---

## Genital Anatomy

- <http://meded.ucsd.edu/clinicalmed/genital.htm>

---

---

---

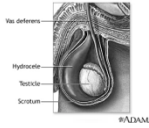
---

---

---

---

## Hydrocele



- Due to a failure of the processus vaginalis to obliterate.
- Extra abdominal peritoneal fluid passes = hydrocele.
- If a viscus passes through, it is a hernia.
- Hydrocele normally resolves a few months after birth.

<http://www.nlm.nih.gov/medlineplus/ency/images/ency/fullsize/19667.jpg>  
<http://www.childclinic.net/surgery/hydrocele.jpg>

---

---

---

---

---

---

---

---

## Diagnosis of Hydrocele

- Transillumination of the scrotum shows a fluid collection.
- A hydrocele that communicates with the peritoneal cavity may increase in size during the day or with the valsalva maneuver.
- Noncommunicating hydroceles are not reducible and do not change in size or shape with crying or straining.
- Not purple, red or discolored.

---

---

---

---

---

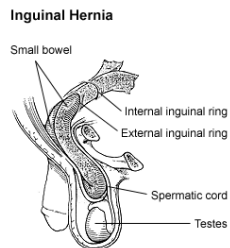
---

---

---

## Inguinal Hernia

- Most common surgical condition of infancy.
- Approximately 60% are on the right side.



<http://wpcontent.answers.com/wikipedia/commons/1/11/Inguinalhernia.gif>

---

---

---

---

---

---

---

---

## Incarcerated Inguinal Hernias

- Risk of incarceration is as high as 60% in the first 6 months of life.
- Should all be referred for repair.

---

---

---

---

---

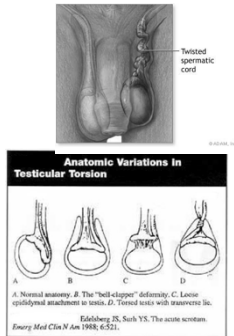
---

---

---

## Testicular Torsion

- May occur in the neonatal age group but more common in adolescents.
- Bell-clapper deformity predisposes.
- Acute onset of pain and nausea.



[http://www.nytimes.com/slideshow/2007/08/01/health/100187TesticularTorsionRepairsSeries\\_2.html](http://www.nytimes.com/slideshow/2007/08/01/health/100187TesticularTorsionRepairsSeries_2.html)

---

---

---

---

---

---

---

---

## Issues to Consider

- Gradual onset of pain may be more consistent with testicular appendiceal torsion or epididymitis.
- Longer than 24 hour duration may indicate necrosis or a non-surgical cause of the pain.

---

---

---

---

---

---

---

---

## Management

- Diagnosis: high riding gonad, anterior facing epididymis, transverse testicle, absent cremasteric reflex.
- Should not wait more than 1-2 hours for any diagnostic testing (refer for emergency surgery).
- Doppler ultrasound, not 100% sensitive, more useful for non-torsion etiologies of scrotal pain.
- Nuclear imaging is about 90% effective, but may take too long to arrange.

---

---

---

---

---

---

---

---

## Scrotal Injuries

- Differentiate from swelling from other causes.
- Doppler ultrasound may be helpful.

---

---

---

---

---

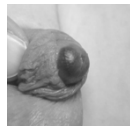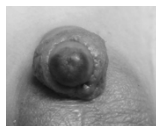---

---

---

## Pinch

- This type of bruising is often a result of a pinch to the penis.
- Determining whether penile injuries such as this resulted from physical abuse or sexual abuse is very difficult.



Visual Diagnosis of Child Abuse, 3rd Edition

---

---

---

---

---

---

---

---

**Interpret Erythema of the Glans**

- Paraphimosis
- Balanitis: Inflammation of the glans
- Posthitis: Inflammation of the foreskin
- Balaposthitis: Inflammation of glans & foreskin
- Hair tourniquet
- Insect bite
- Etiology: nonspecific: External irritation i.e. contact dermatitis; inadequate hygiene of inner prepuccial sulcus
- Carcinoma (rare in children, usually presents with leukoplakia)

Adapted from Peds Clinics North Am. 2006; 53

---

---

---

---

---

---

---

---

**Phimosis and Paraphimosis: Uncircumcised or Partially Circumcised Males**

- Causes of phimosis:
  - Lichen sclerosis
  - Forcible retraction and scarring
- Causes of paraphimosis:
  - Retraction of the foreskin or foreskin manipulation
  - This is an emergency

---

---

---

---

---

---

---

---

**Interpret Erythema of the Shaft**

- Irritants
- Infection
- Trauma
- Self-manipulation
- Balanitis in circumcised male (infection of the shaft) and balanopsthis in uncircumcised male

▪ Note: Classified as "Findings commonly caused by other medical conditions" in Adams JA. **Guidelines for medical care of children evaluated for suspected sexual abuse: an update for 2008.** Curr Opin Obstet Gynecol. 2008 Oct;20(5):435-41.

---

---

---

---

---

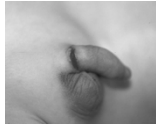---

---

---

## Penis Laceration

- The nearly circumferential superficial laceration at the base of this 2-year-old's penis occurred after his father forcefully pulled on his penis.



AAP Visual Diagnosis of Child Abuse, 3rd Edition

---

---

---

---

---

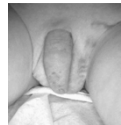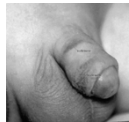---

---

---

## Penis Injuries

- Toilet seat—compression injury.
- Zipper injury



Reference:  
McCann JJ,  
Kerns DL. *The  
Anatomy of  
Child and  
Adolescent  
Sexual Abuse:  
A CD-ROM  
Atlas/  
Reference.*  
1999;  
[www.intercorpinc.com](http://www.intercorpinc.com)

---

---

---

---

---

---

---

---

## Interpret Irritation Noted on Male Genitalia Exam

- Strep balanitis can present with urethral discharge and/or erythema and swelling of the foreskin.
  - Rubbing from sexual abuse.
- Note: Classified as “findings commonly caused by other medical conditions by Adams”

---

---

---

---

---

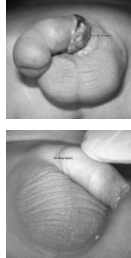
---

---

---

## Tourniquet Injuries

- Injury may result in strangulation, urethrocutaneous fistulas, necrosis and amputation.
- Causes have been reported to include:
  - Hair
  - Rings
  - Bottles
  - Rubberbands
  - Thread or string



Reference:  
McCann JJ,  
Kerns  
DL. *The  
Anatomy of  
Child and  
Adolescent  
Sexual  
Abuse: A  
CD-ROM  
Atlas*.  
Reference.  
1999;  
[www.interco  
rpinc.com](http://www.interco<br/>rpinc.com)

---

---

---

---

---

---

---

---

## Trauma

“Doctor it hurts down there”

---

---

---

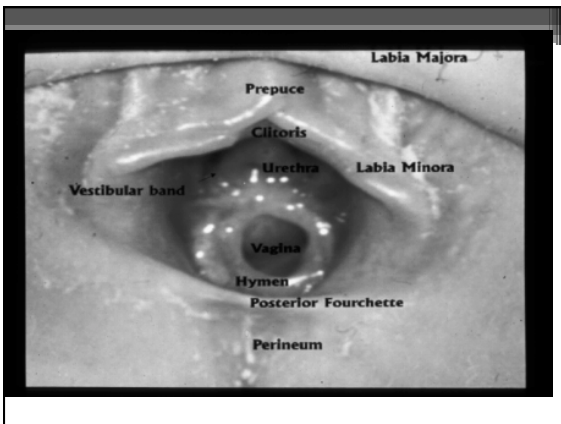
---

---

---

---

---



---

---

---

---

---

---

---

---



## Lichen Sclerosus (et atrophicus)

- Benign, progressive
- Inflammation
- Pruritis, pain
- Two peak incidences: pre-pubertal and post-menopausal
- Trauma may predispose to symptoms in genetically predisposed individuals (Koebner phenomenon)
- Autoimmune dysregulation may be a factor

---

---

---

---

---

---

---

## Lichen Sclerosus

- Painful defecation
- Anal fissures---leading to constipation and cycle of more fissures
- Dysuria
- Biopsy usually not necessary for diagnosis
- Complete ROS for immunodeficiency (thyroid, etc.)
- Check for bacterial and/or fungal infections
- Risk for squamous cell carcinoma

---

---

---

---

---

---

---

## Lichen Sclerosus Treatment

- Relieve pruritis.
- Hygiene, avoidance of bubble baths, pantyhose....
- Superpotent topical steroids:
  - Pick one, use at night for 6-12 weeks, then 3x per week for maintenance
  - Ointments, not creams (more irritants in creams)
- Tacrolimus (calcineurin inhibitors) may have some efficacy – burns with application.

---

---

---

---

---

---

---

### Differential Dx of Gp A Strep

- Diaper dermatitis
- Candidiasis
- Psoriasis
- Seborrheic dermatitis
- Sexual abuse
- Pinworm
- IBD

---

---

---

---

---

---

---

### Treatment for Group A Strep Peri-anal Cellulitis

- Amoxicillin 40 mg/kg per day, TID for 10 days and/or topical applications of mupirocin, 2% TID for 10 days.
- Penicillin, Clindamycin phosphate and erythromycin are also useful.

---

---

---

---

---

---

---

### Testing and Treatment of Genital Herpes in Children

- Typing is not very helpful.
- Antibodies persist indefinitely.
- Acyclovir—for primary genital infection in an immunocompetent host (Red Book recommendations):
  - Oral  $\geq 12$  y 1000–1200 mg/day in 3–5 divided doses for 7–10 days.
  - Oral pediatric dose: 40–80 mg/kg per day divided in 3–4 doses for 5–10 days (maximum 1.0 g/day).
  - IV  $\geq 12$  y 15 mg/kg per day in 3 divided doses for 5–7 days

---

---

---

---

---

---

---

## Treatment for Labial Adhesions

- Estrogen creams
  - Transient side effects
  - 1-2 x per day for a few weeks
- .05% betamethasone
  - 1-3 courses of 2x per day for 4-6 weeks

Goldman R. Estrogen cream for labial adhesion in girls. |  
*Canadian Family Physician* Vol 59: January • 2013

---

---

---

---

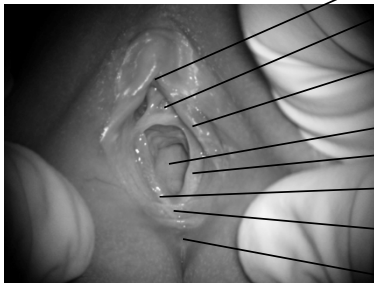
---

---

---

---

## Normal Anatomy



- Clitoris
- Urethra
- Labia minora
- Hymenal orifice
- Hymen
- Fossa navicularis
- Posterior fourchette
- Perineum

---

---

---

---

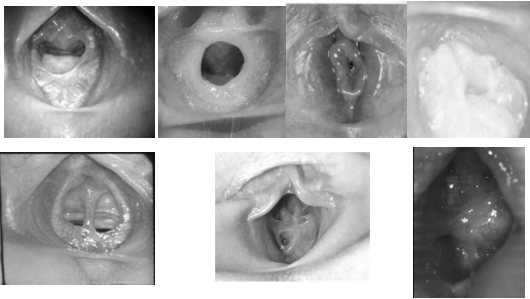
---

---

---

---

## Hymenal Configurations



---

---

---

---

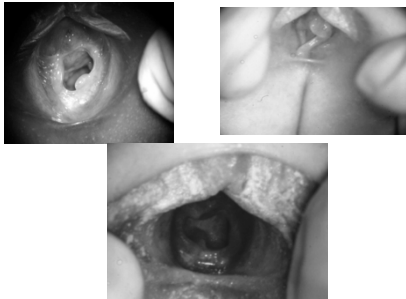---

---

---

---

### Bumps/Mounds/Tags



---

---

---

---

---

---

---

---

### Differential Diagnosis of Genital Bleeding

- <http://www.childabusemd.com/diagnosis/diagnosis-abuse.shtml>

---

---

---

---

---

---

---

---

### Urethral Prolapse

- Typically presents in girls 2-10 years old.
- Bleeding is often the only symptom.
- May or may not have a history of straining.
- If symptomatic in prepubertal girls:
  - Treat with topical estrogen therapy BID
  - Sitz baths twice daily may also be helpful
  - The prolapse will usually resolve
  - Surgery rarely indicated
  - Urethral polyp or other intra-abdominal lesion

---

---

---

---

---

---

---

---

## HPV

- Wart like lesions in the genital or anal area:
  - Indeterminate findings: insufficient or conflicting data from research studies (may require additional studies/evaluation to determine significance).

Adams J. Guidelines for medical care of children evaluated for suspected sexual abuse: an update for 2008. Current Opinion in Ob & Gyn. 2008.

---

---

---

---

---

---

---

---

## Which STDs are commonly transmitted?

- HPV is the most common STD (more than 40% of sexually active teens).
- Anogenital infections are usually subclinical, transmitted by sexual contact. Most are transient and have no clinical consequences.
- More than 40 types can infect the anogenital tract.

---

---

---

---

---

---

---

---

## HPV Risk Factors: Infants and Children

- Sexual abuse
- Maternal HPV, abnormal PAP
- Subclinical oral HPV (maternal or other)
- Diaper changes with transmission of non-genital HPV types to genital surface
- Possibly fomite transmission in household with HPV
- Immunosuppressed state
- Skin abnormalities

---

---

---

---

---

---

---

---

## HPV Clinical Presentation

- Genital HPV infection is usually transient, has no clinical manifestations or sequelae.
- Clinical manifestations of genital HPV infection may include:
  - Genital warts
  - Cervical cell abnormalities
  - Anogenital squamous cell cancers
  - Recurrent respiratory papillomatosis

---

---

---

---

---

---

---

---

## HPV Clinical Appearance

- Condylomata acuminata
  - Cauliflower-like appearance
  - Skin-colored, pink, or hyperpigmented
  - May be keratotic on skin; generally non-keratinized on mucosal surfaces

---

---

---

---

---

---

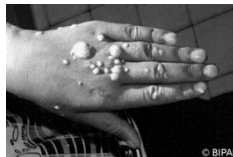---

---

## HPV Clinical Appearance

- Smooth papules
  - Usually dome-shaped and skin-colored

Image 065. 21.  
Human Immunodeficiency  
Virus Infection.  
Severe cutaneous warts  
(human papillomavirus infection)  
in a boy with human  
immunodeficiency virus infection.



Red Book Online Visual Library, 2006. Image 065. 21. Available at:  
<http://aapredbook.aapublications.org/visual>. Accessed May 2009

Copyright ©2006 American Academy of Pediatrics

RED BOOK  
ONLINE

---

---

---

---

---

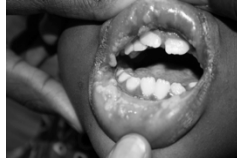---

---

---

## HPV Clinical Appearance

- Flat papules
  - Macular to slightly raised
  - Flesh-colored, with smooth surface
  - More commonly found on internal structures (i.e., cervix), but also occur on external genitalia



ASB Photo with permission

---

---

---

---

---

---

---

---

## HPV Differential Diagnosis

- Normal anatomic variants
  - "Pink pearly penile papules"
  - Vestibular papillae (micropapillomatosis labialis)
  - Skin tags (acrochordons)

---

---

---

---

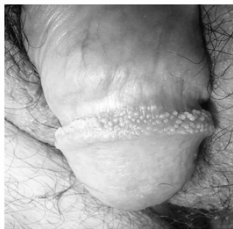---

---

---

---

## Pink Pearly Papules



Kluger N, Dereure O. [Images in clinical medicine. Penile papules](#). N Engl J Med. 2009 Mar 26;360(13):1336.

---

---

---

---

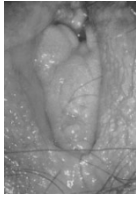
---

---

---

---

## Micropapillomatosis Labialis



<http://www.aafp.org/afp/990315ap/1547.html>

---

---

---

---

---

---

---

---

## HPV Differential Diagnosis

- Acquired dermatologic conditions
  - Seborrheic keratosis
  - Lichen planus
  - Fibroepithelial polyp, adenoma
  - Melanocytic nevus
  - Neoplastic lesions

---

---

---

---

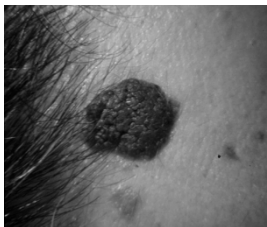---

---

---

---

## Seborrheic Keratosis



<http://courses.washington.edu/hubio567/melanoma/large/mel13.jpg>

---

---

---

---

---

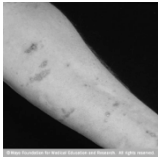
---

---

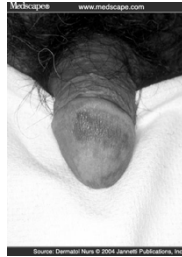---



## Lichen Planus



[http://www.riversideonline.com/source/images/image\\_popup/sn7\\_lichenplanus.jpg](http://www.riversideonline.com/source/images/image_popup/sn7_lichenplanus.jpg)



<http://img.medscape.com/fullsize/migrated/470/167/dm470167.fig1.jpg>

---

---

---

---

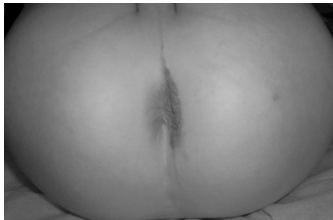---

---

---

---

## Perianal Verrucous Epidermal Nevus



Field, Sinead MB BCh BAO; Buckley, Colin MD, FRCP1, FRCPUK. Perianal Verrucous Epidermal Nevus Mimics a Cutaneous Sign of Child Abuse. *Journal of Pediatrics*. 154(2):306, February 2009.

---

---

---

---

---

---

---

---

## Molluscum Contagiosum

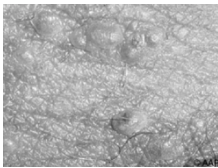


Image 082\_07. Molluscum Contagiosum. A central dimple or umbilication is the hallmark of molluscum contagiosum. The lesions of molluscum contagiosum vary in size from 1 to 6 mm and, unlike venereal warts, are smooth and pearly and have an umbilicated center.

- Molluscum contagiosum-- papules with central dimple, caused by a pox virus; rarely involves mucosal surfaces

Red Book Online Visual Library, 2006. Image 082\_07. Available at: <http://www.redbook.onlinelibrary.com/visual>. Accessed May 4, 2009

Copyright © 2006 American Academy of Pediatrics

RED BOOK ONLINE

---

---

---

---

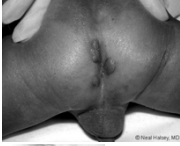---

---

---

---

## Condyloma Lata



- Condylomata lata--tend to be smoother, moist, more rounded, and darkfield-positive for *Treponema pallidum*.

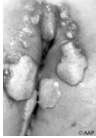

Image 128\_19.  
Syphilis.  
Condyloma latum  
in a 7-year-old girl  
who has been  
sexually abused.

Copyright © 2006  
American Academy  
of Dermatology

Red Book Online Visual Library, 2006. Image 128\_10. Available at: <http://aapp.>

RED BOOK  
ONLINE

---

---

---

---

---

---

---

---

## HPV Pathogenesis

- HPV DNA in infants born to infected mothers ranges from 1%-77% and in uninfected mothers ranges from 1%-50%!
- Vertical transmission via placenta, birth canal and post-neonatal caregiving are possible modes of transmission.
- Sexual transmission occurs on areas of increased friction.

---

---

---

---

---

---

---

---

## HPV Pathogenesis

- The incubation period varies depending on host immune response, virus type and clinical appearance of the lesions.
- Most infections are latent (subclinical infections).
- Perinatal transmission has been theorized to be an average of 8 months, but could be as long as several years.

---

---

---

---

---

---

---

---

## HPV Forensic Interpretation

- The absence of warts in perpetrators does not preclude sexual transmission to a child.

---

---

---

---

---

---

---

## HPV Forensic Interpretation

- Age in years 0-2-3-? Probably perinatally transmitted.
- Older children- sexual transmission more likely, but not definitive.
- Typing HPV is usually not helpful.
- Recurrences may occur, they are not reinfection.
- Considered suspicious if "not likely to be perinatally acquired and rare nonsexual vertical transmission is excluded."

---

---

---

---

---

---

---

## HPV Genotyping

- Ano-genital warts in children are associated with both mucosotropic types HPV 6 and 11 and cutaneotropic types HPV 1 and 2 (Myhre et al.).
- Low-risk types
  - Most visible warts caused by HPV types 6 and 11.
  - Recurrent respiratory papillomatosis associated with HPV types 6 and 11.
- High-risk types
  - HPV types 16 and 18 found in more than half of anogenital cancers.
  - Most women with high-risk HPV infection have normal Pap test results and never develop precancerous cell changes or cervical cancer.

---

---

---

---

---

---

---

## HPV Diagnosis

- Diagnosis is usually made by visual inspection with bright light.
- Diagnosis can be confirmed by biopsy when:
  - Diagnosis is uncertain.
  - Patient is immunocompromised.
  - Warts are pigmented, indurated, or fixed.
  - Lesions do not respond or worsen with standard treatment.
  - There is persistent ulceration or bleeding.

---

---

---

---

---

---

---

---

## HPV Diagnosis

- Use of type-specific HPV DNA tests for routine diagnosis and management of genital warts is not recommended.
- Acetic acid evaluation (acetowhitening) of external genitalia is not recommended.
- External genital warts are not an indication for cervical colposcopy or increased frequency of Pap test screening (assuming patient is receiving screening at intervals recommended by her health care provider).

Adapted from CDC Educator Slides

---

---

---

---

---

---

---

---

## HPV Pros and Cons of Subtyping

- Multiple HPV subtypes may co-exist in the same individual.
- HPV may be subclinical in the perpetrator.
- High prevalence of HPV in the community.
- Cutaneous warts may appear in the genital area and vice versa in children.

---

---

---

---

---

---

---

---

## HPV Pathogenesis

- May regress spontaneously or persist with or without proliferation.
  - Frequency of spontaneous regression is unknown.
  - Persistence of infection occurs, but frequency and duration are unknown.
  - Recurrences after treatment are common.

Adapted from CDC Slide Set for Educators on HPV

---

---

---

---

---

---

---

---

## HPV Treatment Modalities

- Treatment goal is removal of symptomatic warts.
- Provider administered:
  - Cryotherapy with liquid nitrogen or cryoprobe
  - Podophyllin resin 10%-25% in compound tincture of benzoin
  - Trichloroacetic acid (TCA) or bichloroacetic acid (BCA) 80%-90%
  - Surgical removal
- Patient applied regimens:
  - Podofilox 0.5% solution or gel
  - Imiquimod 5% cream

---

---

---

---

---

---

---

---

## HPV Treatment Limitations

- Recurrences frequently occur within 3 months.
- If left untreated, visible genital warts regress spontaneously or persist with or without proliferation.
- Currently available therapies may reduce infectivity, but probably do not eradicate it.
- There is no evidence that presence of genital warts or their treatment is associated with development of cervical cancer.

---

---

---

---

---

---

---

---

### Key Points for Documentation of HPV Infection

- Maternal history
- Exposure within family
- Hand warts on caregivers
- Sexual abuse risk factors
- Other symptoms of STDs
- Age of child
- Descriptors of warts, locations and size
- Generally NOT type

---

---

---

---

---

---

---

---

### Summary Regarding HPV

- The finding of genital warts in children should prompt a medical evaluation for other STDs and possible sexual transmission.
- Based on the age of the child, transmission factors and low risk of sexual abuse, reporting may not be necessary.
- Treatment is rarely complete and disease often recurs.

---

---

---

---

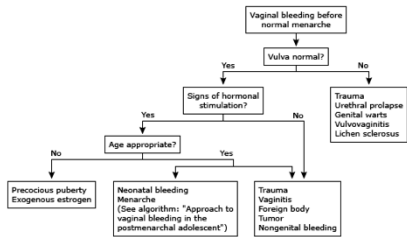
---

---

---

---

#### Approach to vaginal bleeding in the premenarcheal child



Reproduced with permission from: Paradise JE. Vaginal bleeding. In: The Textbook of Pediatric Emergency Medicine, 6th edition, Fleisher GR, Ludwig S, (Eds). Lippincott Williams, & Wilkins, Philadelphia 2010. Copyright © 2010 Lippincott Williams & Wilkins. <http://www.lww.com>

UpToDate®

---

---

---

---

---

---

---

---